

Case Report

Management of Odontogenic Cutaneous Fistula Secondary to Dental Abscess: Report on Two Cases

Ni Putu Natasha Ayu Rupayasa, Nyoman Ayu Anggayanti, Ni Made Ista Prestiyanti

Department of Oral and Maxillofacial Surgery, Faculty of Medicine, Universitas Udayana, Denpasar, Indonesia

Received date: January 15, 2026

Accepted date: April 6, 2026

Published date: April 30, 2026

KEYWORDS

Fistulectomy, odontogenic cutaneous fistula, dental abscess



DOI: 10.46862/interdental.v22i1.13462

ABSTRACT

Introduction: Odontogenic cutaneous fistula is an abnormal pathway that causes pathologic communication between the cutaneous surface of the face skin and the oral cavity that occurs due to a chronic dental infection.

Case: A 37-year-old male presented with frequent throbbing pain in all four wisdom teeth and a sunken scar on the lower left cheek, resulting from a carious lesion in the lower left molar. A 56-year-old female presented with a sunken scar on her cheek following the extraction of an infected upper molar.

Case Management: Both odontogenic cutaneous fistulas were treated by addressing causative tooth infection, when present, in combination with fistulectomy. On follow-up, the first patient exhibited delayed wound closure, whereas the second achieved complete closure through a combined subcutaneous and cutaneous suturing technique. The extraoral fistula may present in various forms, with dimpling or retraction resulting from adherence to underlying tissues. Accurate diagnosis of odontogenic cutaneous fistulas that are often misdiagnosed require careful history taking, clinical evaluation, and radiographic examination. Definitive management typically involves fistulectomy to resolve the extraoral lesion.

Conclusion: Odontogenic cutaneous fistulas are managed by eliminating dental infection and performing fistulectomy, with combined closure optimizing healing and aesthetic outcomes.

Corresponding Author:

Nyoman Ayu Anggayanti
Department of Oral and Maxillofacial Surgery, Faculty of Medicine
Universitas Udayana, Denpasar, Indonesia
Email: ayu.anggayanti@unud.ac.id

How to cite this article: Rupayasa NPNA, Anggayanti NA, Prestiyanti NMI. Management of Odontogenic Cutaneous Fistula Secondary to Dental Abscess: Report on Two Cases. *Interdental Jurnal Kedokteran Gigi*. 2022;22(1):165-172. doi: 10.46862/interdental.v22i1.13462

Copyright: ©2026 [Nyoman Ayu Anggayanti](#) This is an open access article distributed under the terms of the Creative Commons Attribution-ShareAlike 4.0 International License. Authors hold the copyright without restrictions and retain publishing rights without restrictions.

INTRODUCTION

Odontogenic infections arise from endodontic or periodontal dental sources.¹ Failure to manage the affected tooth in the early inflammatory stage increases the risk of complications, often leading to pulp necrosis and spread of infection to the periradicular tissues, resulting in apical periodontitis. Over time, the infection may progress through the cancellous alveolar bone along the path of least resistance, perforate the mandibular cortical plate, extend into adjacent soft tissues, and present as a cutaneous lesion.^{1,2}

An odontogenic cutaneous fistula is defined as an abnormal pathway that causes pathologic communication between the cutaneous surface of the face skin and the oral cavity that occurs due to a chronic dental infection.^{3,4} It is often misdiagnosed as a dermatological lesion, which the patient usually reach physician or dermatologist.⁴⁻⁷ Although dermatologists frequently perform the initial evaluation of such lesions, it is noteworthy that the lesion was successfully identified and properly managed by the oral surgery team.

The prevalence of odontogenic cutaneous fistulas remains unclear; however, they appear to be underreported, with only about ten cases documented in the last ten years.³ The etiology varies, ranging from caries, trauma, pericoronitis, fractured tooth roots, residual roots, impacted teeth, and malfunctional denture repair.⁶

Effective management of odontogenic cutaneous fistulas necessitate elimination of the odontogenic source through procedures such as tooth extraction or endodontic therapy. Several case reports indicate that associated cutaneous lesions may heal spontaneously following dental treatment alone; thus, the indication for surgical intervention of the skin should be determined on a case-by-case basis.⁸ This case report aims to discuss the

diagnosis and procedure of fistulectomy for odontogenic cutaneous fistula management in two case reports.

CASE

Case 1

A 37-year-old male patient came to Udayana Dental Hospital, Bali, Indonesia, with a chief complaint of frequent throbbing pain in all four wisdom teeth, which sometimes caused swollen gums. He also had a sunken scar on his lower left cheek, which had been present for the past two months. The sunken scar was initially caused by a cavity in his lower left tooth, which had caused repeated swelling several times while he was working abroad. The patient stated that the swelling was only drained by a doctor abroad, but the tooth had not yet been treated due to the swelling. The doctor also prescribed the antibiotic Augmentin. The patient admitted that the last swelling was about 2 weeks ago, currently there are no complaints or pain in that area. The patient denied any specific medical history, and the patient's vital signs were within the normal range.

Extraoral examination showed an extraoral fistula in the left mandibular area (Figure 1. (A), (B)). Intraoral examination showed that teeth 18, 28, 38, and 48 were partially erupted and growing obliquely (Figure 1. (C), (D)). Tooth 36 had a restoration on the buccal surface. Tooth 46 was missing, and there were plaque and calculus in the entire maxillary and mandibular region. Panoramic radiographic examination showed that teeth 18, 28, 38, and 48 were impacted, and there was a periapical lesion at the apex of tooth 36 (Figure 2). Based on subjective, clinical, and examination findings, the patient was diagnosed with impacted teeth 18 and 28 in position B SA Distoangular; impacted tooth 38 class IIB Distoangular; impacted tooth 48 class

IA Mesioangular; odontogenic cutaneous fistula et regio mandibular sinistra e.c periapical abscess of tooth 36. The patient had already signed the informed consent to receive odontectomy of teeth 18, 28, 38, 48; extraction of tooth 36; and fistulectomy for the extraoral fistula. The patient has also consented to the documentation of his case for scientific purposes.

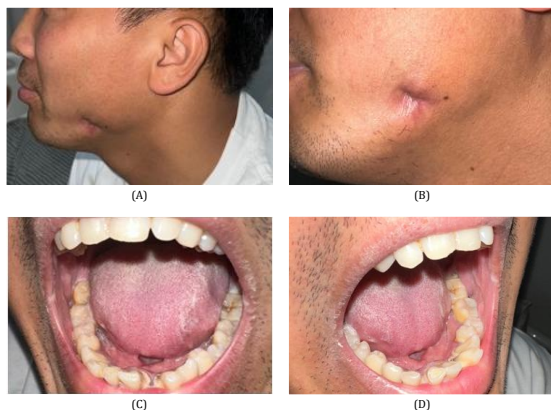


Figure 1. (A), (B) Extraoral pre-operative; (C), (D) Intraoral pre-operative

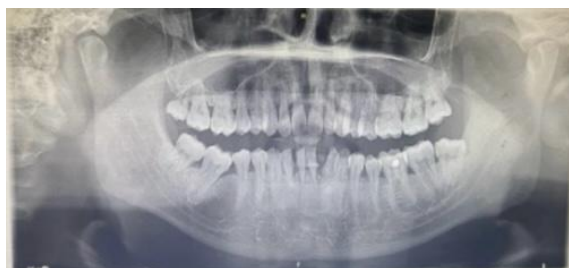

Figure 2. Panoramic radiograph

Case 2

A 56-year-old female patient came to Udayana Dental Hospital, Bali, Indonesia, with the chief complaint of a sunken scar on her cheek. The medical record showed that initially tooth 16 was diagnosed with periapical abscess and periodontitis that was causing pus to come out through the cheek. The tooth was then extracted 3 weeks ago. After the extraction, the hole in her cheek dried out and became sunken, as it is now. The patient wanted the sunken scar to disappear. The patient

has a history of diabetes mellitus, hypertension, high cholesterol, gastroesophageal reflux disease (GERD), and gouty arthritis. She has regular check-ups with an internist at a private hospital and regularly takes medication and insulin injections before meals. Vital signs were all within normal range.

Extraoral examination showed an extraoral fistula in the right buccal area (Figure 3. (A), (B)). Intraoral examination revealed granulation tissue in the post-extraction socket of tooth 16, indicating that healing was progressing well (Figure 3.C). Radiographic examination showed that the bone at the post-extraction site of tooth 16 was in good condition, with only a decrease in the alveolar crest due to periodontitis (Figure 4). Based on subjective, clinical, and supportive examination, the patient was diagnosed with odontogenic cutaneous fistula et regio bucal dextra. The patient had already signed the informed consent to receive fistulectomy as the treatment of choice. The patient had also consented to documenting her case for scientific purposes.

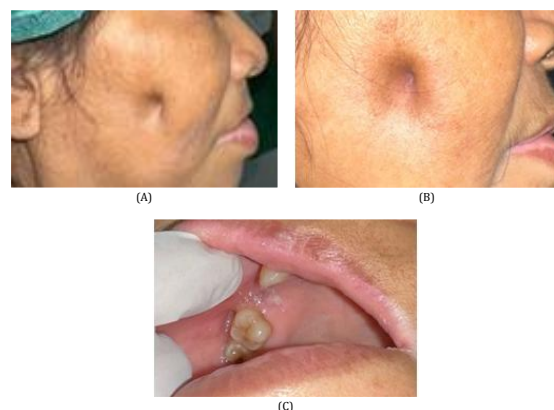


Figure 3. (A), (B) Extraoral pre-operative; (C) Intraoral pre-operative

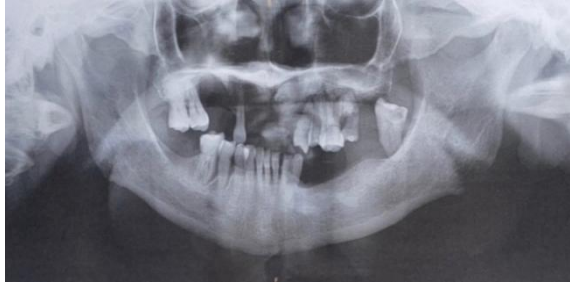

Figure 4. Panoramic radiograph

CASE MANAGEMENT

Case 1.

The patient came on the day of surgery (September 12th 2025), and then the patient was admitted to the hospital for pre-operative observation. The patient's general condition was good, and examination showed his vital signs were normal. The patient had been instructed to fast for eight hours before surgery. At 45 minutes before the surgery, intravenous lactate Ringer solution 20 dpm, Ceftriaxone 1 gr IV, Ketorolac 30 mg IV, Methylprednisolone 125 mg IV, were given to the patient.

The surgery was done under general anesthesia. First, the extraoral and intra-oral asepsis were done with 10% povidone iodine. Then, draping was done using steril cloth and leave only the operation site. Odontectomy for teeth 18,28,38,48 done first, then the extraction and drainage for tooth 36. After that, fistulectomy is carried out. Firstly, an outline was made at the surgical site using a surgical marker. Administration of a solution consisting of one ampule of pehacain diluted 1:1 in 0,9% NaCl was done at the operation site. Incision was made using blade #15 and electrocauter. Once the wound edges approximation and the tissue tension were enough, then suturing was carried out layer-by-layer.

On the D+1 follow-up (September 13th, 2025), clinically, the extraoral wound was observed to be open, with persistent bleeding noted within the area (Figure 5.A). The intraoral condition of the

post-odontectomy area of teeth 18, 28, 38, 48, as well as the post-extraction area of tooth 36, demonstrated satisfactory healing (Figure 5.B). The patient reported no complaints, and wound care was provided to the surgical site. The patient was subsequently discharged. On D+8 follow-up (October 20th, 2025), the patient came with no complaints regarding the surgical scar. Aff sutures was performed, although the surgical site remained slightly open. On the D+4 months (January 10th, 2026) follow-up, extraoral examination demonstrated complete wound closure, and the patient reported satisfaction with the outcome (Figure 6. (A), (B)).

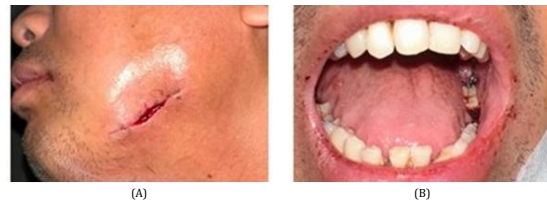

Figure 5. (A) Extraoral D+1 follow-up; (B) Intraoral D+1 follow-up

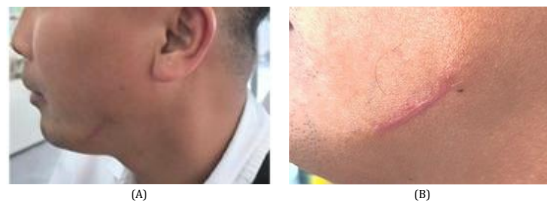

Figure 6. (A) Follow-up D+4 months; (B) Close-up picture of follow-up D+4 months

Case 2.

On the surgery day (October 15th, 2025), the patient was admitted to the hospital for pre-operative observation. The patient's general condition was good. Vital signs were within the normal range. The patient had fasted for eight hours before surgery as instructed. Intravenous lactate Ringer solution 20 dpm, Methylprednisolone 125 mg IV, Ceftriaxone 1 gr IV, Ketorolac 30 mg IV were given

to the patient 45 minutes before the surgery. The patient was also consulted with an internist and was approved for surgery.

General anesthesia was performed on the patient. Asepsis was performed extraorally and intraorally with 10% povidone iodine. The patient was then draped with sterile cloth, exposing only the targeted operative site. An outline was made using a surgical marker. Around the surgical site, the operator also administered a solution consisting of one ampule of pehacain diluted 1:1 in 0,9% NaCl. The incision was then made following the outline and was done layer-by-layer. The incision using blade #15 and electrocauter was also made to release tissue tension in the skin layer (Figure 7.A). Once the tissue tension was felt to be adequate and the wound edges approximation was good, then sutured layer-by-layer (Figure 7. (B)).

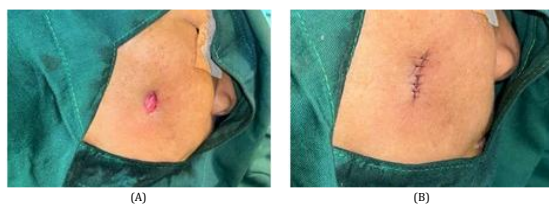


Figure 7. (A) Incision according to the outline; (B) Suturing layer-by-layer

On the D+1 follow-up (October 16th, 2025), the patient stated that there were no complaints and wound care was performed on the surgical area, then the patient was allowed to go home (Figure 8). On D+17 follow-up, November 1st, 2025, the patient came and denied any complaints about the wound. The extraoral examination demonstrated complete wound closure (Figure 9. (A)). An aff suture was performed (Figure 9. (B)). The patient expressed satisfaction with the improved appearance of the hole in her cheek. At this appointment, tooth 24, which was loose to the third

degree, was also extracted to prevent further infection.

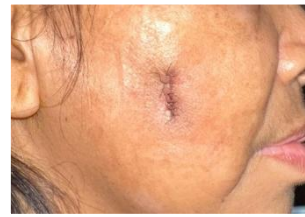

Figure 8. D+1 follow up

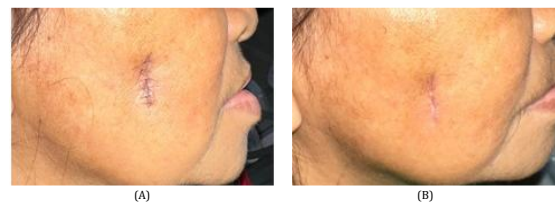

Figure 9. (A) D+17 follow up; (B) D+17 after aff suture

DISCUSSION

Odontogenic cutaneous fistula is a rare condition that is caused by dental origin. Dental trauma or pathology may lead to pulpal necrosis and periapical abscess formation, with chronic inflammation gradually extending through the least resistant path by the alveolar bone into adjacent soft tissues and eventually draining through the skin.^{9,10} The cutaneous manifestations of odontogenic cutaneous fistulas are largely nonspecific and remain poorly characterized in the existing literature. The external opening of the sinus tract may present clinically as cutaneous dimpling, a nodule, abscess, cyst, ulceration, a draining lesion, or a suppurative nodulocystic lesion.⁷ Odontogenic sinus tracts commonly present as painless, palpable facial nodules or pustules, with or without purulent discharge.¹¹ Cutaneous dimpling or retraction may occur due to fixation to underlying tissues.¹² Although some patients report a history of toothache or a palpable intraoral cord, only approximately 50% recall prior dental pain.¹³ In line with these cases, the lesion in the first case

was located on the jaw, and the lesion in the second case was located on the chin.

The cutaneous manifestations of odontogenic fistulas are often nonspecific and are infrequently described in literature. The external opening of a cutaneous sinus tract may present in various forms, including an ulcer, dimple, abscess, nodule, cyst, nodulocystic lesion with suppuration, or draining lesion.⁷ In these case reports, both lesions form in a dimple with tissue shrinkage towards the inside of the lesion. The morphological presentation of odontogenic cutaneous fistulas varied considerably, with dimpling observed in 41% of cases, nodular lesions in 32%, abscess formation in 21%, and cystic lesions in 6%.¹⁴

The variable anatomical presentation of odontogenic cutaneous fistulas often leads to diagnostic challenges, although lesion location generally correlates with the affected tooth.¹⁵ In this report, the first lesion was located in the mandibular jaw region and originated from a mandibular molar, while the second lesion appeared in the cheek region secondary to a maxillary molar infection. Mandibular teeth account for approximately 70–80% of cutaneous odontogenic fistulas, with lesions commonly presenting on the jaw or chin, whereas fistulas of maxillary origin typically manifest on the cheek. Mandibular molars are the most frequently implicated teeth.¹⁶

In most cases, extraoral fistula formation occurred within six months, while a prolonged course was observed in the remaining cases. Diagnostic delay may be primarily attributed to failure to recognize the underlying odontogenic origin, particularly in the absence of overt dental signs or symptoms, as well as the considerable heterogeneity in cutaneous clinical manifestations.¹⁶ In this case report, the operator successfully identified the lesion based on a history of odontogenic

pathology, as both patients reported a preceding toothache followed by the development of a cutaneous dimple scar. Due to their uncommon occurrence and the frequent absence of overt dental symptoms, odontogenic cutaneous fistulas are often misdiagnosed, resulting in delayed or inappropriate management. The differential diagnosis of cutaneous lesions mimicking odontogenic fistulas includes a spectrum of infectious, inflammatory, congenital, and neoplastic conditions. Common considerations are sebaceous cysts, osteomyelitis, thyroglossal duct and branchial cleft fistulas, pyogenic granulomas, actinomycosis, subcutaneous mycoses, chronic tuberculous lesions, localized skin infections such as carbuncles and infected epidermoid cysts, neoplasms including squamous and basal cell carcinoma, and foreign body granulomas.^{2,10,15,17}

Management of odontogenic cutaneous fistulas requires accurate diagnosis due to the wide differential. Panoramic and periapical radiographs are instrumental in identifying cutaneous odontogenic sinuses through radiolucency of the affected teeth, whereas computed tomography (CT) can also be used to provide a detailed evaluation of the infection's extent, including cortical bone disruption, adjacent soft tissue alterations, and paranasal sinus involvement. Once a dental origin is confirmed through extraoral, intraoral, and radiographic assessment, treatment focuses on eliminating the communication between the infection and the skin. This may be achieved via conservative endodontic therapy, endodontic treatment with apical resection, or eliminating the infected tooth through extraction and curettage. This management is also typically accompanied by fistulectomy, involving the surgical excision of the extraoral sinus tract. The sinus tract generally resolves within two weeks, although mild dimpling or hyperpigmentation may

persist, and surgical correction can be performed either after lesion resolution or immediately before or after treatment of the causative teeth.^{9,12} In this case report, the first patient required extraction of the tooth responsible for the ongoing infection, while in the second patient, the source of infection had already been removed, and attention was directed toward surgical correction of the residual dimpled scar.

The outcomes in the two cases differed notably. In the first case, only subcutaneous sutures were placed, without a cutaneous suture, whereas in the second case, both subcutaneous and cutaneous sutures were applied. Consequently, the first patient experienced delayed wound closure, while the second achieved complete closure immediately. These findings align with previous research by Luo et al., which emphasizes that in high-tension areas, combining subcutaneous and cutaneous continuous sutures is essential to minimize wound dehiscence and optimize cosmetic outcomes.¹⁸ This case report highlights the management of odontogenic cutaneous fistulas, emphasizing both the elimination of the focal infection and the improvement of the patient's quality of life by enhancing cosmetic outcomes and self-confidence. Suboptimal results may serve as a reference for other clinicians to refine treatment approaches and achieve better patient outcomes.

CONCLUSION

Odontogenic cutaneous fistulas require accurate diagnosis and definitive management, including elimination of the dental infection and fistulectomy to correct extraoral deformities. Effective wound healing and improved cosmetic outcomes are best achieved by combining subcutaneous and cutaneous closure techniques, which also enhance patient quality of life and self-confidence.

ACKNOWLEDGEMENT

We gratefully acknowledge the patients who consented to participate in this case report. Their willingness to share detailed medical history and experiences was essential for the preparation of this report. Their cooperation and fortitude have contributed significantly to the advancement of medical knowledge and may provide valuable insights for the management of similar cases. We sincerely appreciate their trust and collaboration in supporting the dissemination of clinical findings to improve healthcare practice.

REFERENCES

1. Hupp, J.R., Ellis, E., and Tucker, M.R. Contemporary Oral and Maxillofacial Surgery. 7th ed. Philadelphia: Elsevier, Inc.; 2019. p. 318-322.
2. Figaro, N., & Juman, S. Odontogenic cutaneous fistula: A cause of persistent cervical discharge. Case Reports in Medicine 2018; (1): 3710857. Doi: 10.1155/2018/3710857
3. Bruneau A, Lehner J, Bertolus C, Bohbot AL. Odontogenic cutaneous fistula following wisdom tooth extraction: A Rare Case Report. Cureus 2025; 17(6): e86256. Doi: 10.7759/cureus.86256
4. Taylor RR, Mirsky N, Jabori S, Verling S, Coelho PG, Thaller SR. Odontogenic cutaneous fistula: a zombie diagnosis. Journal of Craniofacial Surgery 2024; 35(4): 1197-1200. Doi: 10.1097/SCS.00000000000010144
5. Srikanth GT, Kamath ABHAY, Kudva A, Singh A, Smriti K, Carnelio S. A linguovered impacted tooth with orocutaneous fistula—a rare case report. Clujul Medical 2018; 91(4): 479. Doi : 10.15386/cjmed-945
6. Xia J, Tang H, Jiang G. A retrospective study of the clinical and imaging features of 60 cases of odontogenic cutaneous fistula. Indian Journal of Dermatology, Venereology and Leprology 2024; 90(6): 777-781. Doi : 10.25259/IJDVL_1059_2023
7. Lee EY, Kang JY, Kim KW, Choi KH, Yoon TY, Lee JY. Clinical characteristics of odontogenic cutaneous fistulas. Annals of Dermatology 2016; 28(4): 417-421. Doi: 10.5021/ad.2016.28.4.417
8. Tsuda T, Gonda K, Tachi K, Takami JA. Case of an external dental fistula originating from a retained tooth fragment in the edentulous maxilla. Journal of Plastic and Reconstructive Surgery 2025; 1(1): 1-6. Doi : 10.53045/jprs.2025-0010
9. Bilginaylar, K. Uncommon odontogenic orocutaneous fistula of the jaw treated with platelet-rich fibrin. Case Reports Dent. 2017; 1(1): 7174217. Doi: 10.1155/2017/7174217
10. Latifa H, Dorsaf T, Amira K, Karim J, Nabiha D. Surgical management of an odontogenic cutaneous sinus tract misdiagnosed for 4 years. Clinical Case Reports 2022; 10(2): e05333. Doi: 10.1002/ccr3.5333

11. Carvalho M, Lopes CF, Catarino MA. Odontogenic cutaneous fistula. *BMJ Case Reports* 2025; 18(1): e263314. Doi: 10.1136/bcr-2024-263314.
12. Chang LS. Common pitfalls of plastic surgeon for diagnosing cutaneous odontogenic sinus. *Archives of Craniofacial Surgery* 2018; 19(4): 291. Doi: 10.7181/acfs.2018.02110
13. Kim NG, Kim JO, Park YJ, Kim JS, Lee YJ, Lee KS. Cutaneous basal cell carcinoma arising in odontogenic cutaneous fistula. *Archives of Craniofacial Surgery* 2017; 18(2): 141. Doi: 10.7181/acfs.2017.18.2.141
14. Ortega MJI, Quiroga ANM. Odontogenic cutaneous fistula: first dermoscopic description and a practical management framework. *Cureus* 2025; 17(9): e92791. Doi: 10.7759/cureus.92791
15. Chhabra A, Chhabra N. Dental infection mimicking dermatological lesion: three case reports of cutaneous fistulae and sinus tracts on the face. *Indian Dermatology Online Journal* 2018; 9(6): 441-444. Doi: 10.4103/idoj.IDOJ_317_17
16. Mashyakh M. Diagnosis, treatment, and recall of a poorly managed submandibular cutaneous fistula of odontogenic origin: a case report utilizing CBCT. *Kuwait Medical Journal* 2024; 56(2): 161-166.
17. Kim YS, Kim BS, Kim HS, In SK, Yi HS, Kim HI, Park JH, Kim HY. A Case of Odontogenic Fistula Misdiagnosed as cutaneous Ulcer on the Alar-Facial Angle. *Journal of Wound Management and Research* 2020; 16(3): 177-181. Doi: 10.22467/jwmr.2020.01249
18. Luo W, Tao Y, Wang Y, Ouyang Z, Huang J, Long X. Comparing running vs interrupted sutures for skin closure: A systematic review and meta-analysis. *International Wound Journal* 2023; 20(1): 210-220. Doi: 10.1111/iwj.13863